The superiorly based bilobed flap for nasal reconstruction

Michael Kelly-Sell, MD,[a,b] S. Tyler Hollmig, MD,[c] and Joel Cook, MD[a]
Charleston, South Carolina; Clinton Township, Michigan; and Redwood City, California

Background: The laterally based bilobed flap is commonly used for the reconstruction of small- to medium-sized defects of the distal portion of the nose; However, when this flap is used to repair defects that are larger, more cephalic, or more lateral on the nose, there is a risk for lower nasal distortion. Reorienting the base superiorly preserves the advantages of the traditional design while minimizing this risk.

Objective: To demonstrate the design, execution, and efficacy of the superiorly based bilobed flap.

Methods: A retrospective review examined all superiorly based bilobed flaps performed by 1 surgeon (J.C.) in 2000-2016 after tumor extirpation by Mohs micrographic surgery at a single institution.

Results: A total of 41 surgical defects were closed with 40 flaps between June 2000 and August 2016 (1 patient had 2 defects closed with a single flap). Of the tumors, 55% were located on the nasal dorsum, and the median of the longest postoperative tumor axis was 1.4 cm. Follow-up was available for 40 flaps, and no infections, hematomas, or episodes of full-thickness necrosis were observed.

Limitations: Data were collected retrospectively from a single institution without a standardized assessment tool for aesthetic outcomes.

Conclusion: The superiorly based bilobed flap is useful for nasal reconstruction. (J Am Acad Dermatol 2018;78:370-6.)

Key Words: bilobed flap; facial reconstruction; Mohs micrographic surgery; nasal reconstruction; superiorly based bilobed flap; transposition flap.

The laterally based bilobed flap is commonly used for the aesthetic and functional repair of small- to medium-sized nasal defects of the supratip and lateral nasal tip.[1,2] For these defects, the bilobed flap offers distinct advantages over alternative repairs: access to an adjacent tissue reservoir with similar aesthetic qualities, predictable flap viability, and the reduced morbidity of a single-stage procedure.[3] In the traditional design, the vascular inlet, or base, of the bilobed flap is located laterally, where tributaries of the angular artery provide a robust vascular supply to nourish the flap.[4] This design harvests the available lax skin of the nasal dorsum to repair more distal nasal defects and is the criterion standard in lower nasal repair for many surgeons.[1,4]

However, with the traditional design, it may be a struggle to deliver reproducible aesthetic success for nasal defects with a diameter larger than 1.0 cm, wounds located on other parts of the nose, or patients with thick skin on the nasal dorsum. In such circumstances, the closure of the flap's terminal

From the Department of Dermatology and Dermatologic Surgery, Medical University of South Carolina, Charleston[a]; Midwest Skin Cancer Surgery Center, Clinton Township[b]; and Department of Dermatology, Stanford University Medical Center, Redwood City.[c]

Supported by the Department of Dermatology and Dermatologic Surgery, Medical University of South Carolina.
Conflicts of interest: None declared.
Presented at the 2017 American College of Mohs Surgery, San Francisco, CA; April, 27, 2017.

Accepted for publication September 2, 2017.
Reprints not available from the authors.
Correspondence to: Michael Kelly-Sell, MD, Midwest Skin Cancer Surgery Center, 43900 Garfield Rd, Suite 129, Clinton Township, MI 48038. E-mail: mkellysell@dmsderm.com.
Published online October 19, 2017.
0190-9622/$36.00
© 2017 by the American Academy of Dermatology, Inc.
https://doi.org/10.1016/j.jaad.2017.09.014

donor site on the nasal dorsum or sidewall may introduce a significant risk for permanent lower nasal distortion (Fig 1). To circumvent this problem, we reoriented the base (or pivot point) from a lateral to a superior location and moved the terminal donor site from the nose to the paranasal cheek. This preserves the geometric advantages of the traditional bilobed flap while harvesting an aesthetically similar donor site with less risk for anatomic distortion. Herein we report our experience with the superiorly based bilobed flap for the reconstruction of nasal defects.

CAPSULE SUMMARY

- The laterally based bilobed flap has anatomic restrictions that may limit its utility for nasal reconstruction.
- Reorienting the base superiorly moves the terminal donor site off the nose and decreases the risk for lower nasal distortion.
- The superiorly based bilobed flap preserves the advantages of the traditional design and expands the utility of this flap.

METHODS

The Medical University of South Carolina Institutional Review Board approved this study (Pro00058644). We performed a retrospective review of all Mohs micrographic surgery defects repaired with a bilobed flap by a single surgeon (J.C.) after tumor clearance between June 2000 and August 2016. All Mohs micrographic surgical procedures were performed with clean technique, and all closures were performed with sterile technique.[5]

All Mohs micrographic surgical cases and subsequent repairs during this period were recorded in a commercially available database (Microsoft Access, Microsoft Corporation, Redmond, WA, and Malachite Corporation, Durham, NC). The database was searched for all adult patients (18 years or older) who had a bilobed repair of a surgical defect on the nose. Postoperative photos were then reviewed to determine the location of the base (lateral, medial, superior, or inferior). All cases with a superiorly based design and documented follow-up were included in our study. Data were collected on tumor sublocation, tumor type, tumor size at presentation, postoperative defect size, postoperative prescriptions, and surgical complications, which included hematoma, infection, flap necrosis, and nasal valve dysfunction (as recorded in the patients' medical record during the 4 months after surgery). Follow-up photos taken at 4 months or later were reviewed for all flaps to determine aesthetic results.

As with any bilobed flap, correct design is critical to achieve operative success. Flaps were designed as a random pattern transposition, as described by Zitelli, but with the vascular base, or pivot point, oriented superiorly toward the mid glabella or ipsilateral medial canthus (Fig 2).[4] A Burow triangle from the surgical defect is directed toward the pivot point and should be both perpendicular to the alar margin (to avoid contralateral alar distortion on flap inset) and long enough to form a 30-degree angle, eliminating redundant skin at the point of rotation.[6] The widths of the primary and secondary lobules are designed nearly equivalent to the width of the primary defect. This decreases secondary motion and the concomitant risk for nasal distortion while also limiting the risk for pincushioning, which occurs more often when the lobules are oversized. The primary lobule is designed on the part of the nose abutting the surgical defect, and the amount of skin available on the nose to create this lobule generally limits the size of the defect that can be repaired, as extending this lobule onto the cheek could blunt the nasofacial sulcus. The secondary lobule is then placed on the paranasal cheek adjacent to the melolabial fold as in a nasolabial transposition flap—with its inferior edge within the melolabial fold and a Burow triangle extending caudally.[7] This placement ultimately hides the incision lines in the melolabial fold with minimal aesthetic penalty. The flap's arc of rotation should be adjusted to place the secondary lobule as described, and as with all rotating flaps, the surgeon must account for some shortening of the lobules as a result of pivotal restraint.

As in a traditional bilobed flap, we excise the Burow triangle extending from the surgical defect first to allow for more accurate placement of the primary lobule.[6] The primary lobule is then incised and raised in the submuscular plane while beginning at the nasofacial sulcus, the secondary lobule is undermined in a subcutaneous plane. The entire surgical defect should be widely undermined to minimize the trapdoor effect.[7] Hemostasis is attained with electrocoagulation, taking care to not damage the sebaceous nasal skin. The tertiary defect is first closed to "push" the primary and secondary lobules toward their desired positions. Use of a periosteal suspension suture to anchor the advancing cheek to the pyriform aperture may be helpful to decrease tension on the flap but is not typically required. The secondary lobule is then lifted into position, rather than slid, to avoid blunting the nasofacial sulcus.

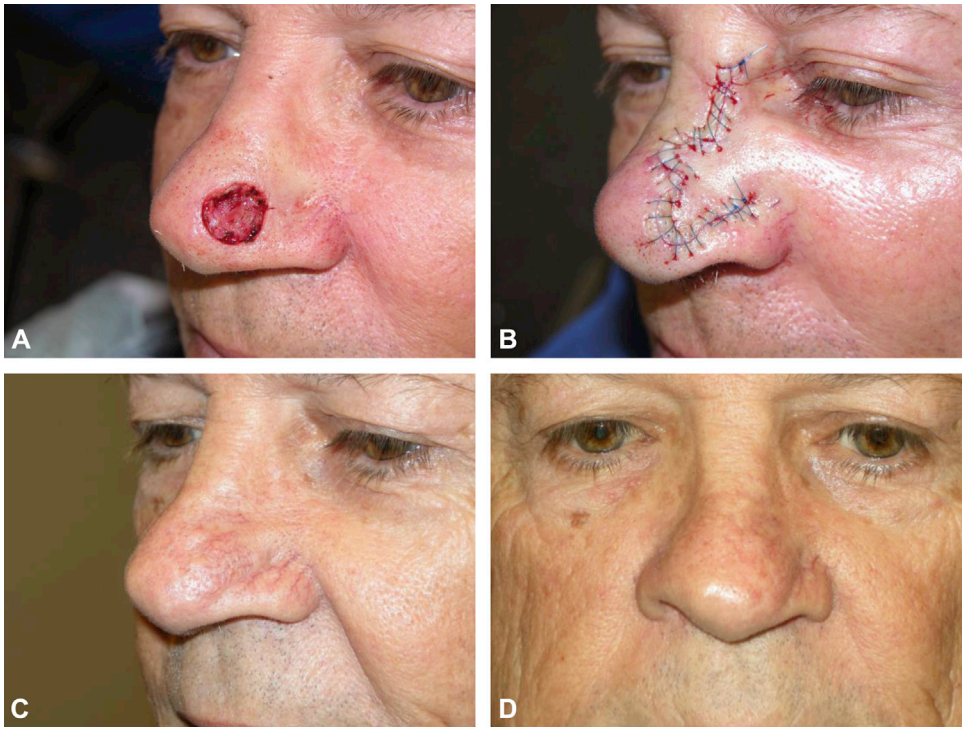

Fig 1. Contralateral alar elevation after repair of a surgical defect on the lateral tip with a traditional bilobed flap. **A,** Postsurgical defect. **B,** Postoperative repair. **C** and **D,** Five-year follow-up demonstrating permanent contralateral alar elevation.

After closure of the tertiary defect, the flap's lobules are inset with meticulous use of buried vertical mattress sutures and the epidermis is closed with a simple running suture.[8]

All surgical wounds were dressed with petrolatum, nonstick gauze, and surgical tape. Patients were instructed to change their dressings and clean their wounds daily. Sutures were generally removed 7 days after surgery. Patients were prescribed a 5-day course of a cephalosporin unless contraindicated, in which case clindamycin or trimethoprim-sulfamethoxazole was generally substituted. Preoperative antibiotics were not typically prescribed unless the patient had had a joint replacement within the past year.

RESULTS

Our data base search found 1137 cases involving a bilobed flap in an adult patient within the study period. Upon reviewing postoperative photos, we identified 41 superiorly based bilobed flaps performed to repair 42 nasal defects (1 patient had 2 defects on the nose that were closed with 1 flap). One flap was excluded, as there was no documented follow-up in the medical record. The remaining 40 flaps were performed between August 2012 and the end of the study period. Figure 3 shows the distribution of tumor sublocations, with the most common tumor locations being the nasal dorsum (55%), tip (18%), and ala (13%). The median of the longest preoperative tumor axis was 0.8 cm (range, 0.4-1.6 cm) and the median of the longest postoperative tumor axis measured 1.4 cm (range, 0.8-2.3 cm). In all, 14 surgical defects (35%) had a postoperative measurement larger than 1.5 cm.

Medical records for the patients' 1-week and 4-month postoperative office visits with their surgeon (J.C.) were available for all 40 flaps. Complications were uncommon—with no increased frequency versus that with traditionally oriented bilobed flaps.[9] There were no cases of infection, hematoma formation, or nasal valve dysfunction. No flap showed complete or full-thickness necrosis; 2 flaps showed superficial or partial distal flap necrosis, with 1 requiring a revisionary procedure. This patient was a former smoker and had a good final aesthetic outcome. This was the only revisionary flap performed in our series. The second case involved the formation of a superficial eschar on the distal flap that resolved with regular use of petrolatum and monitoring.

Typical aesthetic outcomes for patients are shown in Figs 4 and 5, with any refinement procedures performed before the final outcome noted. Secondary procedures to fine-tune the aesthetic result were performed on a minority of flaps:

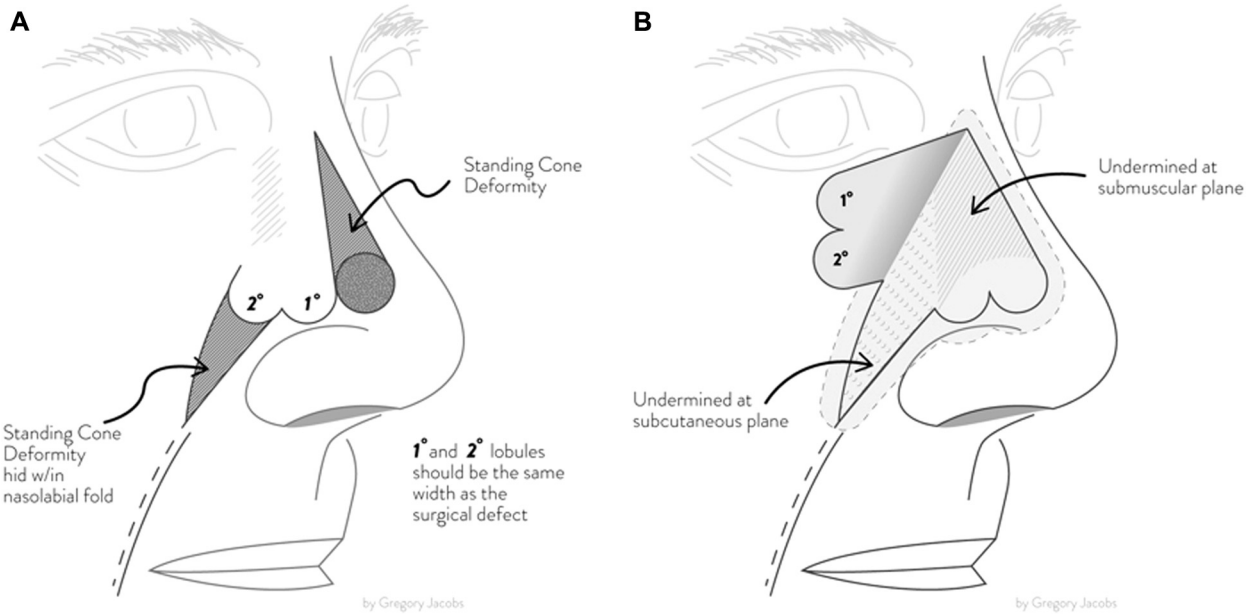

Fig 2. The design and raising of a superiorly based bilobed flap. **A,** All lobules should be equivalent in width to the surgical defect, with the secondary lobule placed abutting the melolabial fold. **B,** The primary lobule is raised in a submuscular plane, whereas the secondary lobule is raised in a subcutaneous plane. The area surrounding the flap should be undermined, as marked. *w/i*, Within. Figure courtesy of Gregory Jacobs. All rights reserved.

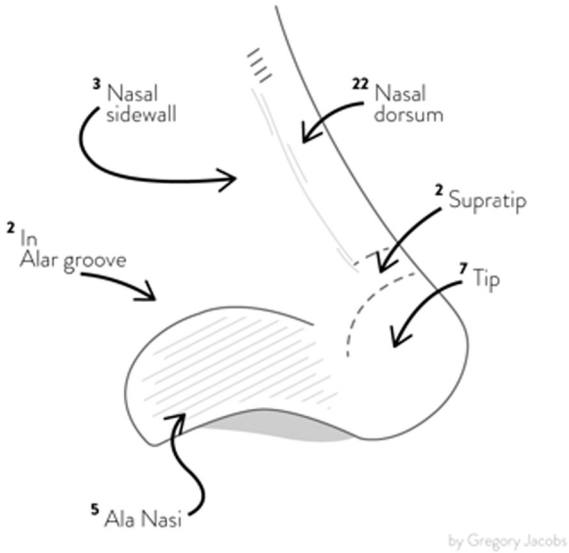

Fig 3. Numbers of tumors located at each nasal sublocation. Figure courtesy of Gregory Jacobs. All rights reserved.

8 flaps were refined with dermabrasion in the office (20%), 3 flaps were treated with a 585-nm pulsed dye laser (8%), and 2 flaps had minor scar revisions (5%), such as the excision of a small (<1 cm) hypertrophic scar. These are similar to the rates reported for a traditional bilobed flap.[9] Importantly, there was little distortion of lower nasal anatomy and no blunting of the nasofacial sulcus. We observed 1 case of iatrogenic alar elevation and 1 patient with prominent scarring and telangiectasias (Fig 6). These patients did not have secondary refinement procedures.

DISCUSSION

Herein, we have described our experience with 40 superiorly based bilobed flaps used to repair 41 surgical defects on the nose. We found that this flap is particularly useful to repair defects that are larger than 1.5 cm in diameter, located off the nasal tip, or located on patients with thick nasal skin. In our series, 14 defects (35%) had a postoperative measurement of their longest axis larger than 1.5 cm, which is commonly considered the upper limit for a defect to be repaired with a traditional bilobed flap. However, by moving the terminal donor site to the medial cheek (which is a larger and more forgiving tissue reservoir), it is possible to reconstruct these defects with less risk for lower nasal distortion. Furthermore, with rotation of the pivot point, it was possible to use this flap to repair many surgical defects located on the nasal dorsum, a location that a traditional design may struggle to repair on account of geometric and mechanical restraints. We believe that with some slight design modifications this, flap may be used to repair defects located on the nasal root, which is an area for further study. Conversely, the superiorly based bilobed flap is not well suited for repair of defects on the lower

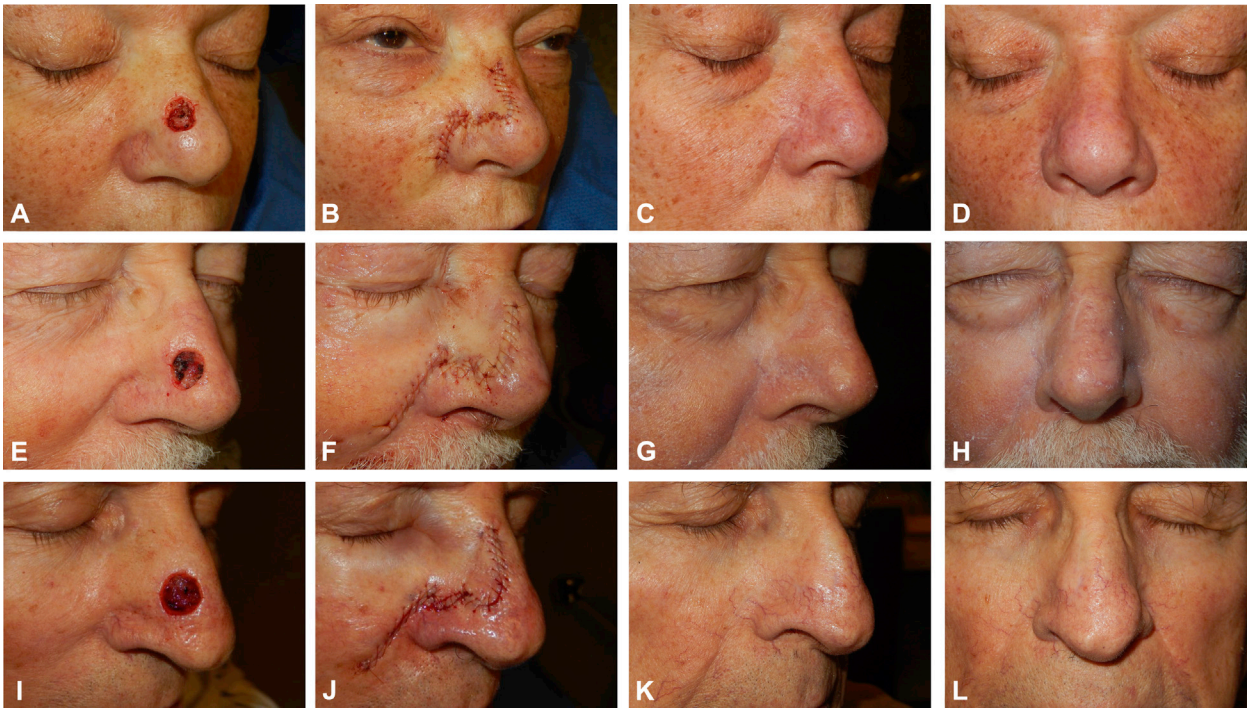

Fig 4. Surgical repairs utilizing a superiorly based bilobed flap. Postsurgical defects measuring 1 × 1 cm **(A),** 1.2 × 1.1 cm **(E),** and 1.2 × 1.3 cm **(I)**. **B, F,** and **J,** Postoperative repair. **C, D, G, H, K,** and **L,** Final aesthetic outcome. Patient shown in **(A)** through **(D)** was treated with pulsed dye laser.

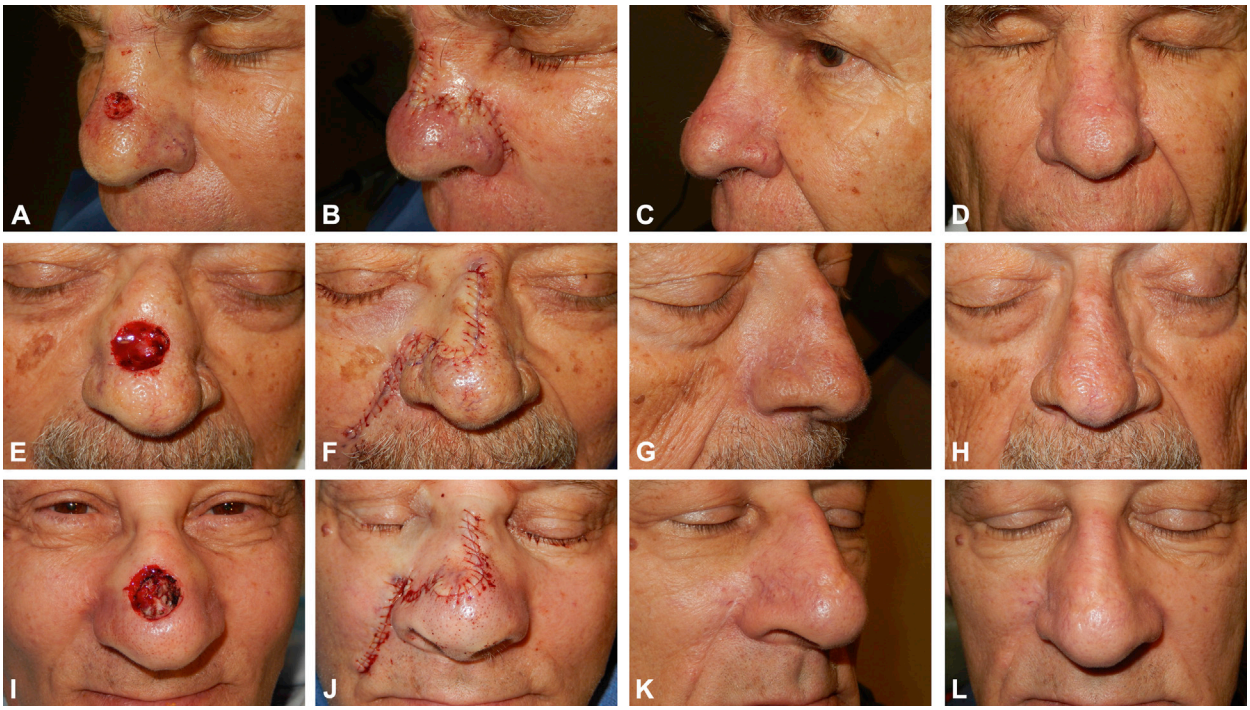

Fig 5. Surgical repairs utilizing a superiorly based bilobed flap. Postsurgical defects measuring 0.8 × 0.8 cm **(A)**, 1.8 × 1.7 cm **(E)**, and 1.6 × 1.7 cm **(I)**. **B, F,** and **J,** Postoperative repair. **C, D, G, H, K,** and **L,** Final aesthetic outcome. Patient shown in **(E)** through **(H)** was treated with dermabrasion.

Fig 6. Potential aesthetic complications of a superiorly based bilobed flap. Postsurgical defects measuring 1.1 × 1.1 cm **(A)** and 1.2 × 1.4 cm **(E)**. **B,** and **F,** Postoperative repair. **C** and **D,** Final aesthetic outcome showing prominent scarring with telangiectasias. **G** and **H,** Final aesthetic outcome showing ipsilateral alar elevation.

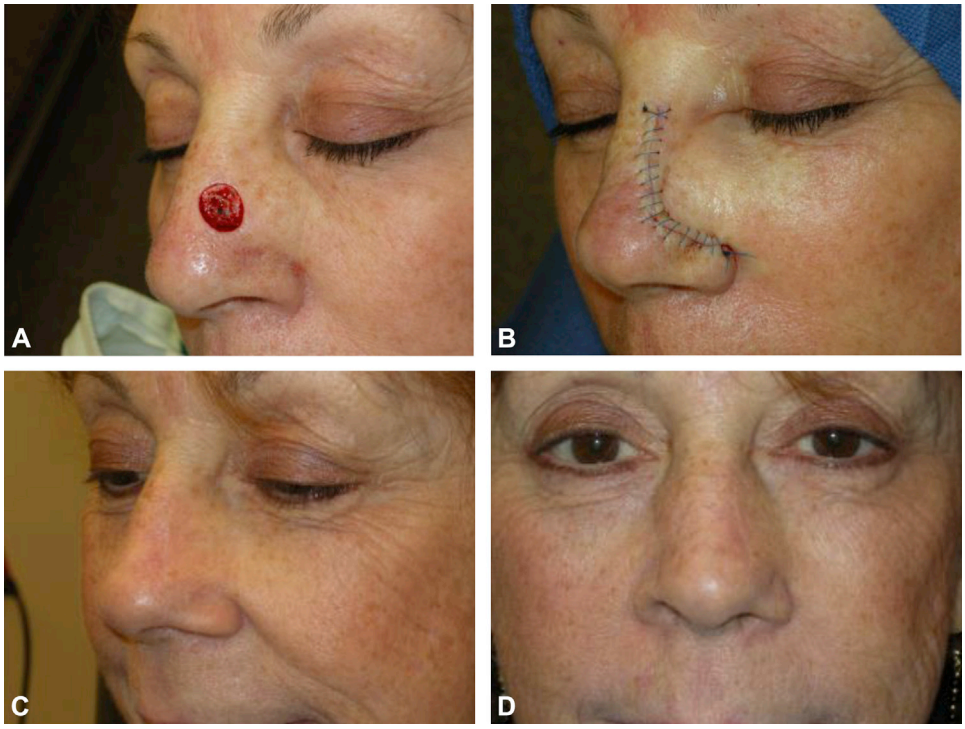

Fig 7. Blunting of the nasofacial sulcus and depression of the ipsilateral ala after repair with a cheek advancement flap. **A,** Postsurgical defect. **B,** Postoperative repair. **C** and **D,** Final aesthetic outcome.

nasal tip and infratip, as pivotal restraint would require the primary lobule to extend onto the alar rim, which is unacceptable. Finally, we have found that this flap is useful in patients with tight nasal skin, where closure of a terminal donor site on the nose may be challenging and options for local flap repairs are limited. Harvesting skin from the medial cheek, which often has some laxity, and using the decreased arc of rotation from the bilobed design allows these nasal defects to be closed with a local flap.

Alternative repair techniques may be used for many of the wounds illustrated in this article, but we think that they are less than ideal for a variety of reasons. Sliding flaps, in particular, the cheek advancement flap, are often used to repair defects on the nasal sidewall, but they tend to bridge the

nasofacial sulcus when used for wounds that are either too large or are located too far anteriorly on the nose. These flaps can cause a visually distracting loss of the shadowed concavity delineating the cheek and nose as separate cosmetic subunits, even when appropriate periosteal tacking sutures are utilized. Furthermore, the pushing effect of the flap may cause ipsilateral alar depression (Fig 7). The nasolabial transposition flap is best suited for defects located on the lateral nose, as the arc of rotation to reach the nasal dorsum and supratip requires an excessively long flap that is quite prone to development of trapdoor deformity or distal necrosis.[7] The superiorly based bilobed flap mobilizes the same tissue reservoir with a smaller arc of rotation. Dorsal nasal rotation flaps serve as a reasonable single-stage alternative for centrally located wounds of the supratip and dorsum, but they are prone to elevate the nasal tip when used for defects with a sizeable horizontal component. These wounds are typically more easily addressed with a tissue reservoir located lateral to, rather than above, the primary defect. The trilobed flap is an excellent reconstructive option for distal defects on the nasal tip and ala, but we believe that it is not ideal for more proximal defects on the nasal dorsum.[10] Finally, although interpolation flaps, such as the paramedian forehead flap, are the criterion standard for complex nasal reconstruction, these surgical procedures are demanding on patients and require multiple procedures.

As with any reconstructive technique, this flap has potential limitations. Flap design and suture technique must be meticulous, because as with other round flaps, there may be a tendency to "trapdoor" and create a visible scar along the inferior margins of the flap. Using primary and secondary lobules that are nearly equivalent in size to the surgical defect and suturing so that these lobules sink concavely into surrounding coarse nasal skin can almost always avoid this complication. Furthermore, during repair of distal defects, the alar groove may be blunted if the primary lobule extends onto the body of the ala. For these defects, we place a tacking suture on the underside of the flap that recreates the alar groove at the correct anatomic position. This suture should be oriented vertically on the underside of the flap so as not to constrict the blood supply.[7]

In summary, we have demonstrated that the superiorly based bilobed flap offers reproducibly excellent results for nasal reconstruction. By changing the orientation of the vascular pedicle and placing the terminal donor site on the medial cheek, this flap allows for the reconstruction of nasal defects with significantly less risk for lower nasal distortion. We believe that this design modification expands the utility of the bilobed flap for nasal reconstruction and complements the traditional design.

The authors would like to thank Mr Gregory Jacobs for his help in designing and creating the illustrations for this manuscript.

REFERENCES

1. Burget GC, Menick FJ. Repair of small surface defects. In: Burget GC, Menick FJ, eds. *Aesthetic Reconstruction of the Nose*. St. Louis, MO: Mosby; 1994:117-156.
2. Baker SR. *Local Flaps in Facial Reconstruction*. 3rd ed. Philadelphia, PA: Elsevier Saunders; 2014.
3. Cook JL. Reconstructive utility of the bilobed flap: lessons from flap successes and failures. *Dermatol Surg*. 2005;31(8 Pt 2):1024-1033.
4. Zitelli JA. The bilobed flap for nasal reconstruction. *Arch Dermatol*. 1989;125(7):957-959.
5. Trufant JW, Marzolf S, Leach BC, Cook J. The utility of full-thickness skin grafts (FTSGs) for auricular reconstruction. *J Am Acad Dermatol*. 2016;75(1):169-176.
6. Cook JL. A review of the bilobed flap's design with particular emphasis on the minimization of alar displacement. *Dermatol Surg*. 2000;26(4):354-362.
7. Zitelli JA. The nasolabial flap as a single-stage procedure. *Arch Dermatol*. 1990;126(11):1445-1448.
8. Zitelli JA, Moy RL. Buried vertical mattress suture. *J Dermatol Surg Oncol*. 1989;15(1):17-19.
9. Moy RL, Grossfeld JS, Baum M, Rivlin D, Eremia S. Reconstruction of the nose utilizing a bilobed flap. *Int J Dermatol*. 1994;33(9):657-660.
10. Albertini JG, Hansen JP. Trilobed flap reconstruction for distal nasal skin defects. *Dermatol Surg*. 2010;36(11):1726-1735.